

Management of eosinophilic granuloma localized in the pelvis and extremities

Management of eosinophilic granuloma

Recep Öztürk¹, Şefik Murat Arıkan², Emin Kürşat Bulut², Galip Beltir², Bedii Şafak Güngör²

¹Department Of Orthopaedics And Traumatology, Polatlı Public Hospital,

²Department Of Orthopaedics And Traumatology, Ankara Oncology Training and Research Hospital, Ankara, Turkey

Abstract

Aim: Given the benign biology, and clinical course of eosinophilic granuloma and its higher incidence in pediatric patient group, a successful treatment plan with lower risk for complications is desired. In this study, we aimed to evaluate clinical characteristics, treatment, and outcomes of patients diagnosed with eosinophilic granuloma localized in the pelvis and extremities. **Material and Method:** Clinical findings, treatment methods, clinical outcomes and treatment failures were evaluated in a total of 19 patients (6 males, 13 females, mean age: 16.5 years, range: 1-37 years) diagnosed with eosinophilic granuloma localized in the pelvis and extremities between 2002 and 2016. **Results:** The most common mass localization was acetabulum (15%, n = 3). The mean tumor size was 3,7 cm (range: 1-8 cm). All patients presented with pain and had primary tumor. All patients in the study had solitary bone lesion. The mean duration of postoperative follow-up was 46 months (range: 24-95 months). Three patients underwent biopsy alone, and followed-up with adjuvant therapies. In 14 patients, curettage of the lesion was performed at single session during biopsy, and grafting was applied in six of these patients. Two patients underwent excision of the lesion. None of the patients developed recurrence, while a new lesion was detected in the cervical vertebra in one patient after treatment of acetabulum localized lesion. **Discussion:** The management of eosinophilic granuloma localized in the pelvis and extremities takes place in a wide spectrum varying from observation alone, to lesion curettage, chemotherapy and radiotherapy applications, and prophylactic administration, and treatment tailored for each patient should be planned with a multidisciplinary approach.

Keywords

Eosinophilic Granuloma; Treatment; Long Bone; Pelvis

DOI: 10.4328/ACAM.6007 Received: 19.08.2018 Accepted: 27.10.2018 Published Online: 01.11.2018 Printed: 01.01.2020 Ann Clin Anal Med 2020;11(1):6-9

Corresponding Author: Recep Öztürk, Polatlı Public Hospital, Ankara, Turkey. GSM: +905054634794 E-Mail: ozturk_recep@windowslive.com

ORCID ID: <https://orcid.org/0000-0002-6753-9321>

Introduction

Also known as histiocytosis X, Langerhans cell histiocytosis (LCH) contain three different conditions including eosinophilic granuloma, Hand-Schüller Christian and Letterer-Siwe diseases [1,2].

Eosinophilic granuloma is a benign form of the disease progressing with solitary or multiple bone involvement. Although the common localizations of involvement include flat bones and especially the skull, it also may be seen in the long bones of extremities. It is known as a childhood disease, but it may be developed also in adults [2-4].

Radiologic appearance of the eosinophilic granuloma is highly variable, and it can mimic many benign or malignant tumors, and infections with hyperbolic MRI findings [5, 6].

The lesion can be followed-up alone because of its benign course once histopathological diagnosis is established. Further treatment is needed in the lesions with a painful course and develop the risk of fracture or deformity [4, 7, 8].

In this study, we aimed to present the analysis of patients diagnosed with eosinophilic granuloma whom follow-up and treatment were carried out in our center for a 15-year period.

Material and Methods

Patients treated and followed-up in the orthopedics and traumatology clinic of our hospital with the diagnosis of eosinophilic granuloma between 2002 and 2016 were retrospectively examined. The study included only the patients who had a histopathological definitive diagnosis. The patients evaluated in the outpatient clinic, who also had Langerhans cell histiocytosis in the differential diagnosis with radiologic clinical features and followed-up without requiring tissue biopsy were excluded from the study.

Terms “eosinophilic granuloma” and “Langerhans cell histiocytosis” were searched among the data from 2002 when pathology database of our orthopedics clinic was established in 2016. Patients’ data were obtained from the orthopedics oncology files involving clinic and radiologic evaluations at first admission and follow-up of the patients, from operation and pathology reports, and from face-to-face or phone interviews with the patients or their relatives, when deemed necessary.

The study included a total of 19 patients with 13 being female and 6 male with a mean age of 16,5 years (range: 1 – 37 years) who had the diagnosis of eosinophilic granuloma on histopathologic examination. A written informed consent was obtained from all patients. This study followed principles of the Declaration of Helsinki.

Patients history, physical examination, posteroanterior chest X-ray, MRI investigations of the affected extremity and routine laboratory outcomes were studied. All patients were assessed by a team consisting of an orthopedist, a radiologist, a pathologist, a medical oncologist, and radiation oncologist. Treatment and follow-up were planned and implemented with a multidisciplinary approach (Figure 1).

All patients were evaluated for the age of admission, localization of the primary tumor, symptoms, and findings, tumor size, type of the surgical procedure, and recurrence.

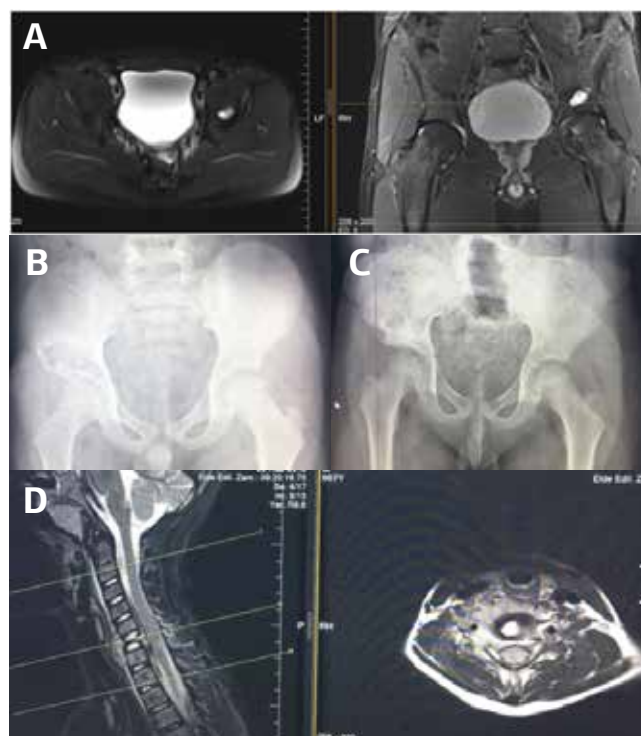


Figure 1. A 37-year-old male, left iliac wing 20x12x15 mm, central area hypointense, periphery mild hyperintense, a capsular cystic mass showing mild enhancement. A 6-year-old male, a mass lesion of 45x29 mm showing growth toward acetabulum ceiling in the right iliac bone (A). A direct X-ray on postoperatif month (B). The same patient developed vertebral plana on the 12th month of postoperative follow-up (C).

Statistical analysis

Statistical analysis was performed using SPSS 22.0 statistical software (SPSS, Chicago, IL, USA). Descriptive statistics are expressed as the mean \pm standard deviation, frequency, and percentage.

Results

All patients presented with primary tumors at the first admission and all patients had localized disease at the time of diagnosis. The most common localization of lesions was acetabulum (n=3, 15%). Of the lesions two (10%) were localized in the diaphyseal femur, two (10%) in the proximal femur, two (10%) in the diaphyseal humerus, two (10%) in the ilium, two (10%) in the ischium, one (5%) in the diaphyseal fibula, one (5%) in the proximal humerus, one (5%) in the clavicle, one (5%) in the scapula, one (5%) diaphyseal tibia, and one (5%) in the proximal ulna.

All patients had localized pain which was the main complaint of admission. None of the patients in this series had systemic findings that may accompany to this lesion (fever, leukocytosis, increased sedimentation rate, and liver dysfunction etc.)

Three patients underwent diagnostic biopsy only as a surgical intervention. The first of them was an 8-year-old male patient with a lesion in the right diaphyseal fibula. He was followed-up after confirming the diagnosis and developed regression at follow-up. The second one was a 1-year-old infant with a lesion in the left proximal ulna. He was given five cures chemotherapy after confirming the diagnosis. The lesion was regressed with the administration of chemotherapeutic agents. The third patient a 10-year-old patient with a lesion in contact with the

main vascular structures which showed invasion toward the acetabulum ceiling. He received a low dose radiotherapy after confirming the diagnosis.

A total of eight patients with lesions in the scapula, iliac wings, proximal femur, and ischium underwent curettage alone. In all of these patients, the curettage operation was performed upon intraoperative frozen examination and was evaluated as benign in nature. Six patients underwent grafting along the curettage at the same time considering the localization, size, and characteristics of the lesion, one of them underwent prophylactic internal fixation. Two patients underwent en bloc resection. A 10-year-old girl patient with a lesion localized in the left diaphyseal femur, and a 17-year-old male patient with a lesion localized in the left clavicle underwent en bloc resection.

The mean tumor size was 3,7 cm (range: 1 – 8 cm). The mean duration of follow-up was 46 months (range: 24-95 months). None of the patients developed recurrence during follow-up. In one patient, no pathology was detected on the 12th month of the follow-up after treatment applied due to the acetabular lesion, but the patient had lesion in the cervical vertebra and developed vertebra plana. The patient was referred to the neurosurgery department with the operation plan.

Discussion

Also known as histiocytosis X, Langerhans cell histiocytosis (LCH) is a rare disorder of the myeloid dendritic cells. However, immune system dysregulation, neoplastic processes, and viruses have been discussed for the pathogenesis of LCH [9, 10]. According to the histiocytosis study group, Langerhans cell histiocytosis was divided into three groups in 1987. LCH consists of three separate diseases including eosinophilic granuloma (EG), Hand-Schuller Christian disease and Letterer-Siwe disease [11, 12].

Hand-Schuller Christian disease progresses with diabetes insipidus, exophthalmos, and lytic lesions and is observed in 15 – 40% of patients. Letterer disease progresses with diffuse involvement in the bone marrow, lymph nodules, central nervous system, skin, and lungs, and is observed in less than 10% of patients. This disease is common in infants and children, and it has a rapid and poor prognosis [13-15].

EG is the most benign localized form among LCHs with the best prognosis. It is often localized in the skull, and the other areas of common involvement include flat bones such as vertebra, mandibula, costa, and pelvis [4]. In addition, involvement of the long bones such as femur, tibia, humerus may be seen. In this study, we included cases of pelvis and extremity lesions that were treated and followed-up in the orthopedics clinic. Considering the included areas, in our study, the most common involvement was in the pelvis, consistently with the literature. Long bones of the extremity were followed by scapula and clavicle with less frequency.

Eosinophilic granuloma has been often diagnosed in early periods of life and is rare in adulthood age groups [3]. In our study also 12 of the patients aged under 18 years, and the youngest patient was 12 months old.

Although the bone involvement of eosinophilic granuloma is usually monostotic, polyostotic involvement has been reported in 10% of patients [16]. In our study, multiple involvements was

seen in only one patient (5%).

Radiologic findings of eosinophilic granuloma may be highly variable. It can mimic many primary bone tumors and infections. Especially, hyperbolic medullary involvement and soft tissue involvement on magnetic resonance imaging often make the differential diagnosis difficult. It can be commonly confused with Ewing's sarcoma and osteomyelitis that are localized in the long bone diaphysis, because these three diseases can involve a wide segment, can make permeative or piecemeal form bone destruction and can produce periosteal reaction [6,17,18]. The definitive diagnosis of histiocytosis X disease group is established with histopathological investigations as the case in many tumoral lesions. In addition, staining of histiocytoses with S-100 and CD1a antibodies with immunohistochemical technique is used in the diagnosis [13]. Definitive diagnoses of our all cases were established based on these data. Treatment of eosinophilic granulomas covers a wide spectrum depending on the degree of organ involvement and local damage. Among these, there are follow-up, surgical curettage, radiotherapy, chemotherapy, and local steroids are treatment options. These options should be tailored to each individual patient and can be used alone or in combinations. The lesions with a painful course, pathologic risk of fracture in load-bearing bones, and those producing non-acceptable dysfunction and deformity require further treatment [4, 7, 8, 18].

Today, follow-up and treatment of benign tumoral lesions can be made in many orthopedics clinics in Turkey [19, 20]. Since our clinic is a tertiary orthopedic oncologic clinic, the majority of our patients were those referred from outer centers with the presumed diagnosis of malignant bone tumors and had aggressive MRI or painful manifestation. Therefore, although it is known from the literature searching that, most of the eosinophilic granulomas are only followed-up due to their benign progression, our study included a group of patients who required slightly more advanced treatment than the literature.

A low dose radiotherapy is a treatment option which has been used especially in the cases where surgical treatment is not possible for a long time and it is currently used in eligible cases. Particularly side effects of radiotherapy are determinants in making decision for this option [21, 22]. In our series, radiotherapy was applied in only one patient, and regression of the lesion was noted following the treatment.

Curettage and augmentation of the space are performed in the load bearing lesions that have fracture risk and produce dysfunction or deformity. In addition, osteosynthesis techniques can also be used for a strong reconstruction [18, 23]. In the present study, only one case required osteosynthesis.

Another treatment method is chemotherapy which can be used alone or as a part of combined treatment. There are studies recommending chemotherapy in cases of load bearing component and especially soft tissue component [24, 25]. In our study, chemotherapy was performed in one patient.

This study has some limitations. The study includes a retrospective evaluation and reflects data of only one clinic. Further multicenter prospective studies with a larger series of patients are warranted.

Scientific Responsibility Statement

The authors declare that they are responsible for the article's scientific content including study design, data collection, analysis and interpretation, writing, some of the main line, or all of the preparation and scientific review of the contents and approval of the final version of the article.

Animal and human rights statement

All procedures performed in this study were in accordance with the ethical standards of the institutional and/or national research committee and with the 1964 Helsinki declaration and its later amendments or comparable ethical standards. No animal or human studies were carried out by the authors for this article.

Funding: None**Conflict of interest**

None of the authors received any type of financial support that could be considered potential conflict of interest regarding the manuscript or its submission.

References

- Ozturk R. Kemik ve yumuşak doku tümörleri. In: Atay T, editors. Ortopedi ve spor yaralanmaları asistan kitabı. 1st ed. Ankara: Derman Tıbbi Yayıncılık; 2015. p.635-704.
- Bahadır A, Erduran E. Lymphadenopathy of A Newborn: Langerhans Cell Histiocytosis. Acta Oncol Tur. 2015; 220-3.
- Plasschaert F, Craig C, Bell R, Cole WG, Wunder JS, Alman BA. Eosinophilic granuloma a Different Behaviour in Children Than in adults. J Bone Joint Surg [Br]. 2002; 84-B: 870-2
- Erol B, States L, Pawel BR, Tamai J, Dormans JP. Musculoskeletal tumors in children. In: Dormans JP, editors. Pediatric Orthopaedics and Sports Medicine: The Requisites in Pediatrics. Philadelphia: Mosby; 2004. p. 299–336.
- Basmacı M, Hastürk AE. Eozinofilik Granüloma: Radyolojik ve Klinik Değerlendirme Türk Nöroşirürji Dergisi. 2011; 21(3): 262-4.
- Meyer JS, De Camargo B. The role of radiology in the diagnosis and follow-up of Langerhans cell histiocytosis. Hematol Oncol Clin North Am 1998; 12: 307–26.
- Tun K, Türkoğlu ÖF, Okutan Ö, Özer O, Özlem Ö. Eosinophilic Granuloma in the Young Adult Patient: A Case Report. Journal of Neurological Sciences 2005; 22: 421-4.
- Sessa S, Sommelet D, Lascombes P, Prévot J. Treatment of Langerhans-cell histiocytosis in children. Experience at the Children's Hospital of Nancy. J Bone Joint Surg Am. 1994; 76: 1513–25.
- Ribeiro KB, Degar B, Gianotti Antoneli CB, Rollins B, Rodriguez-Galindo C. Ethnicity, Race, and Socioeconomic Status Influence Incidence of Langerhans Cell Histiocytosis. Pediatr Blood Cancer. 2015; 62: 982–7.
- Glantzbecker MP, Carpentieri DF, Dormans JP. Langerhans cell histiocytosis: a primary viral infection of bone? Human herpes virus 6 latent protein detected in lymphocytes from tissue of children. J Pediatr Orthop. 2004; 24: 123–9.
- Writing Group of the Histiocyte Society. Histiocytosis Syndromes in children. Lancet. 1987; 1: 208-9.
- DeMarino DP, Dutcher PO Jr, Parkins CW, Hengerer AS. Histiocytosis X: otologic presentations. Int J Pediatr Otorhinolaryngol. 1985; 10: 91-100.
- Bölükbaşı Fh, Kakşi M, Ayan E, Zemheri E, Çerçi A, Elmacı İ. Kafa Travması Öyküsü Olan Çocuk Hastada Eozinofilik Granülom. Göztepe Tıp Dergisi. 2010; 25(4): 196-200.
- Lipton JM. Histiocytic disorders. Hoffman R, Benz EJB, Shattil SJ, Furie B, Cohen HJ, Silberstein LE, Mc Glave P, editors. In Hematology, Basic Principles and Practice. 3rd ed. Churchill Livingstone; 2000: 783-96.
- Hocazade C, Doğan M, Yorulmaz A, Güreşçi S, Cılız D, Evrim E, et al. Atypical Presentation In Langerhans Cell Histiocytosis: Hearing Loss, Diabetes Insipidus, & Extensive Cutaneous Lesions with Nail Dystrophy. Acta Oncol Tur. 2017; 50(1): 76-80
- Lieberman PH, Jones CR, Steinman RM, Erlandson RA, Smith J, Gee T, et al. Langerhans cell (eosinophilic) granulomatosis. A clinicopathologic study encompassing 50 years. Am J Surg Pathol. 1996; 20: 519–52.
- Erol B, Segal L, Huff D, States L, Dormans JP. Low back pain in a 13-year-old girl. Clin Orthop Relat Res. 2003; 413: 323–31.
- Erol B, Sofulu Ö, Topkar MO, Çalışkan E, Türköz HK. Long-term follow-up of long and flat bone eosinophilic granulomas managed only with biopsy. Acta Orthop Traumatol Turc. 2015; 49(2): 144-50.
- Öztürk R, Aydın M, Arıkan M, Toğral G, Aydın G, Güngör BŞ. The report of tumor resection prosthesis infection due to Sphingomonas paucimobilis. Acta Oncol Tur. 2016; 49(1): 57-60.
- Öztürk R, Arıkan ŞM, Şimşek MA, Özanel E, Güngör BŞ. Management of solitary fibrous tumors localized in extremity: case series and a review of the literature. Eklem Hastalik Cerrahisi. 2017; 28(2): 121-7.
- Broadbent V, Gardner H. Current therapy for Langerhans cell histiocytosis. Hematol Oncol Clin North Am. 1998; 12: 327–38.
- Womer RB, Raney RB Jr, D'Angio GJ. Healing rates of treated and untreated bone lesions in histiocytosis X. Pediatrics. 1985; 76: 286–8.
- Komp DM, Born LP. Langerhans cell histiocytosis. In: Moosa AR, Schimpff SC, Robson MC, editors. Comprehensive textbook of oncology. 2nd ed. Baltimore: Williams & Wilkins; 1991. p. 1582–6.
- Starling KA. Chemotherapy of histiocytosis-X. Hematol Oncol Clin North Am. 1987; 1: 119–22.

25. Velez-Yanguas MC, Warriar RP. Langerhans' cell histiocytosis. Orthop Clin North Am. 1996; 27: 615–23.

How to cite this article:

Öztürk R, Arıkan ŞM, Bulut EK, Beltir G, Güngör BŞ. Management of eosinophilic granuloma localized in the pelvis and extremities. Ann Clin Anal Med 2018; Ann Clin Anal Med 2020;11(1):6-9